

Do Barbed Sutures Make a Difference in Laparoscopic Pyeloplasty? A Single Centre Experience Comparing V-LocTM and Vicryl for Adult Pelvi-ureteric Junction Obstruction

Dr Tarun Javali¹, Dr Varun G Huilgol², Dr Manasa T^{*3}, Dr Puvvada Sandeep⁴, Dr Yashas Prasad Mylarappa⁵

¹Professor of Urology, Ramaiah Medical College, Bengaluru, Karnataka, India.

²Assistant Professor of Urology, St. Johns Medical College, Bengaluru, Karnataka, India.

³Associate Professor of Urology, Ramaiah Medical College, Bengaluru, Karnataka, India.

⁴Additional Professor of Urology, Ramaiah Medical College, Bengaluru, Karnataka, India.

⁵Observer in Urology, Ramaiah Medical College, Bengaluru, Karnataka, India.

*Corresponding Author: Dr Manasa T, manasat7@gmail.com

Abstract

Introduction: Laparoscopic intracorporeal suturing is technically challenging with a much steeper proficiency gaining curve. Although barbed self-retaining sutures have been employed effectively for various laparoscopic procedures requiring suturing, their role in laparoscopic pyeloplasty has not been well studied. Therefore, we aimed to compare the efficacy and outcomes of barbed vs non barbed sutures for laparoscopic pyeloplasty in adults. **Methods:** Between January 2020 and December 2023, all adult patients satisfying the eligibility criteria who underwent laparoscopic pyeloplasty either using 4-0 V-LocTM 90(Group1) or 4-0 Vicryl suture (Group2) were retrospectively evaluated. Both the groups were compared for patient demographics, perioperative and post-operative variables, complications, and renal function. Success was defined as the absence of clinical symptom combined with a patent unobstructed or improved/stable renal function on a DTPA renogram. **Results:** 90 patients fit the eligibility criteria with 45 in each group. Demographic and clinical criteria were comparable. Congenital PUJO (54.4%) was the most common aetiology with anterior crossing vessel in 12 patients. Mean intracorporeal suturing time (32.78 ± 12.32 minutes) and the mean total operative time (153.54 ± 20.56 minutes) was significantly shorter in the V-LocTM group (p<0.0001). None of the laparoscopic pyeloplasties were converted to open procedure. Post-operative drain removal and hospital stay was significantly delayed in the vicryl group. Perioperative and post-operative complications were similar with a success rate of 97.7%. No deterioration of function was noted on follow up DTPA renogram. Median follow up duration was 2.3 years with 1 in each group developing recurrence. **Conclusion:** Laparoscopic transperitoneal pyeloplasty using unidirectional barbed suture(V-LocTM) is safe and feasible with similar functional outcomes and significantly lesser operative times.

Keywords: Laparoscopic pyeloplasty; Pelviureteric junction obstruction; V-LocTM 90.

Introduction

Intracorporeal suturing and knotting is regarded as the most technically challenging aspect of any laparoscopic procedure [1]. Acquiring skill and technique requires a steep learning curve; is tedious leading to increased operative times and may cause tissue necrosis due to excessive tightening on the knots [1,2]. Loosening of the knots is also a common complication [3]. In order to vanquish the adversities related to intracorporeal suturing, various advancements such as the tissue sealants and glues, and intracorporeal staplers have been introduced [2]. Barbed self-retaining sutures are novel sutures aimed to address the same problems by providing knot-free tissue approximation thus minimising operative times and reducing complications [2,3].

Use of barbed sutures in laparoscopic pyeloplasty has been reported by very few urologists, albeit with mixed results. Liatsikos *et al.* [2] reported a high stricture rate post pyeloplasty with barbed sutures, describing the suture material as unfavourable. The particular barbed suture used in this study was Quill suture (Angiotech, Vancouver, British Columbia). Sorokin *et al.* [1] performed robotic pyeloplasty in adults with unidirectional barbed 4/0 V-LocTM suture (Covidien, Mansfield, MA) with favourable outcomes. While V-LocTM sutures have demonstrated successful outcomes for laparoscopic pyeloplasty in children, [3] the literature is scarce prompting further evaluation. Furthermore, no studies till date have been performed in adult population comparing the barbed vs non barbed suture head to head for laparoscopic pyeloplasty. Therefore, we retrospectively evaluated all adult patients undergoing laparoscopic pyeloplasty using conventional 4-0 Vicryl (Polyglactin

910) (ETHICON, US) 4-0 suture vs 4-0 V-Loc™ 90 and compared their efficacy and outcomes.

Materials and Methods

On obtaining institutional ethical committee approval, we retrospectively evaluated all adult patients attending the Urology outpatient department with Pelvi-ureteric junction obstruction (PUJO) and subsequently planned for laparoscopic transperitoneal dismembered pyeloplasty between January 2020 and December 2023.

Inclusion Criteria: Age: >18 years < 60 years, Primary/Secondary/Recurrent PUJO, CT scan showing predominantly extrarenal pelvis, and a functional scan demonstrating >15ml/min glomerular filtration rate on the affected side. All patients diagnosed to have concomitant presence of stone disease, active UTI and those undergoing non dismembered pyeloplasty were excluded from the study.

In all patients, diagnostic work up included a complete medical history, urinalysis with culture, serum creatinine, renal ultrasonography, Contrast enhanced CT scan of Kidney Ureter and Bladder (CECT KUB) with urography and 99Tc-DTPA renography. All patients had radiographic evidence of PUJO on CECT KUB with deterioration of renal function and delayed clearance of radioisotope on DTPA renal scan. Eligible patients were randomised into two groups in a 1:1 ratio using sealed envelope sequence. Group 1 underwent laparoscopic pyeloplasty using 4-0 V-Loc™ 90 and Group 2 using 4-0 Vicryl suture.

All procedures were performed by two highly skilled laparoscopic surgeons with one preferring V-Loc™ and the other preferring Vicryl. Both the surgeons had similar years of experience with good technical expertise and both performed laparoscopic pyeloplasty using the transperitoneal approach. A retrograde pyelogram was performed intraoperatively prior to the laparoscopic procedure and a 14Fr Foley's catheter placed. With the patient in 45 degree flank position, one 10 mm port and two 5 mm ports were placed following creation of a pneumoperitoneum using a Veress needle. An additional 5 mm trocar was placed to aid in dissection and retraction if needed. With the right armamentarium, the renal pelvis, PUJ and upper part of the ureter was dissected and mobilised. Pelvis was incised with scissors and the stenotic portion with the redundant pelvis was excised if necessary. The pelvi-ureteric anastomosis was performed initially starting with the posterior layer followed by the anterior wall over a 5Fr Double J (DJ) stent (Cook Medical, Bloomington, USA). The reconstruction was performed using continuous sutures using 4-0 V-Loc™ in Group 1 and 4-0 Vicryl in Group 2. A 14Fr drain was placed and secured. Foleys catheter was removed 48 hours post procedure and the drain subsequently in the event of no increase in the output in the next 24 hours as per institution protocol. Drain removal was delayed if the output was more than 30 ml.

In both the treatment groups, oral fluid intake was initiated on the first postoperative day, based on patient's tolerance to feeds and bowel movements with regular alimentation achieved by the third post-operative day. Patients were discharged on the day of drain

removal. Perioperative parameters were assessed including operative time, intraoperative blood loss, number of sutures used, time taken for intracorporeal suturing, postoperative pain, haematuria, fever and duration of hospital stay.

DJ stent removal was scheduled at 4 weeks post operatively. A DTPA renogram was performed in all patients 6 weeks from stent removal followed by 3, 6 and 12 months post pyeloplasty as per department protocol.

Success was defined as the absence of clinical symptom combined with a patent unobstructed or improved/stable renal function on a DTPA renogram. Data compiled and statistical analysis was done using independent t test, Fisher Exact test and Chi square test. A p value of <0.05 was considered statistically significant.

Results

Between January 2020 and December 2023, we performed 139 adults laparoscopic transperitoneal pyeloplasties. Of the 139 patients, only 90 patients fit the eligibility criteria and were included in the study with 45 patients in each group. Demographic and clinical criteria were comparable across both the treatment groups (**Table 1**). Anterior crossing vessel was identified in 12 patients (13.33%). 7 (7.78%) patients had B/L PUJO with bilateral pyeloplasty performed in the same sitting. Congenital PUJO (54.4%) was the most common etiology with 34.4% patients presenting with a palpable abdominal mass. 12 (13.33%) had undergone a prior laparoscopic pyeloplasty and 6 (6.67%) open pyeloplasty. Assessment of parenchymal thickness on both Ultrasound and CT scan were comparable. No laparoscopic pyeloplasty was converted to open procedure. Mean total operative time was shorter in the V-Loc™ group by 27 minutes, with the mean intracorporeal suturing time 32.78 ± 12.32 minutes. The vicryl group took extra 21 minutes intracorporeal suturing which was statistically significant (p<0.0001). While the Foley's catheter was removed on the 2nd day in almost all cases, post-operative drain removal was significantly delayed in the group 2 by a mean of 3.98 ± 0.61 days from the day of surgery (Day of surgery counted as day 1). This subsequently led to delay in discharge extending the hospital stay to 4.37 ± 1.10 days. Meanwhile those in Group 1 averaged at 3.11 ± 0.1 days for drain removal postoperatively with the duration of hospital stay being 3.62 ± 1.38 days. All patients were stented and stent was removed at 4 weeks post operatively (**Table 2**).

Perioperative and post-operative complications are illustrated in Table 3. Postoperative DTPA revealed no obstruction in 44/45 (97.7%) in Group 1 with similar incidence in Group 2. The improvement in the split renal function between preoperative and postoperative DTPA renogram is depicted in Table 4. There was no worsening in relative renal function from preoperative to postoperative for any patient. Two patients developed post-operative pain roughly 6 months post procedure and the DTPA confirmed obstruction (T1/2 greater than 20 minutes) in both the patients with 1 each in both the groups. Success rate was 97.7% which was similar in both the treatment groups. Both patients with recurrence had undergone prior pyeloplasty and subsequently underwent uretero-calycostomy. Median follow up duration was 2.3 years with all patients having > 1 year follow up.

Table 1: Demographic criteria across both the treatment groups(n=90):

Variables	V-Loc™(n=45)	Vicryl(n=45)	P value
Age(years)	35.449 ± 7.55	36.76 ± 8.12	0.43*
Gender			
Male	31(68.89%)	34(75.56%)	0.48†
Female	14(31.11%)	11(24.44%)	

Body mass index(kg/m ²)	24.72± 2.44	25.12 ± 1.94	0.392*
Laterality			
Bilateral	4(8.89%)	3(6.67%)	1‡
Right	21(46.67%)	21(46.67%)	
Left	20(44.44%)	21(46.67%)	
Abdominal mass	16(35.56%)	15(33.33%)	0.824‡
Aetiology of PUJO			
Inflammation	5(11.11%)	4(8.89%)	0.881†
Congenital obstruction	24(53.33%)	25(55.56%)	
Crossing vessels	7(15.56%)	5(11.11%)	
Stricture	9(20%)	11(24.44%)	
Pre operative Percutaneous nephrostomy(PCN)	5(11.11%)	3(6.67%)	0.714‡
Previous surgery			
Lap pyeloplasty	7(15.56%)	5(11.11%)	0.535†
Open pyeloplasty	4(8.89%)	2(4.44%)	0.677‡
CT findings			
Presence of stone on CT	-	-	-
Parenchymal thickness on CT(mm)	12.09±1.28	12.3+1.11	0.408*
Perinephric fat stranding	-	-	-
USG findings			
AP diameter of pelvis on USG(mm)	33.7± 12.6	34.3± 12.4	0.82*
Parenchymal thickness on USG	12.24± 1.09	12.47± 1.01	0.302*

* Independent t test, † Chi square test, ‡ Fisher Exact test

Table 2: Perioperative and post-operative data compared across both the treatment groups(n=90):

Variables	V-Loc TM (n=45)	Vicryl(n=45)	P value
Number of sutures	2.33± 1.66	4.66± 1.33	<.0001*
Reduction pyeloplasty			
Performed	4(8.89%)	5(11.11%)	1.00
Not performed	41(91.11%)	40(88.89%)	
Type of surgery- dismembered	45(100%)	45(100%)	-
Total operative time	153.54 ± 20.56	180.43 ± 22.67	<.0001*
Time taken for intra-corporeal suturing	32.78 ± 12.32	53.52± 13.75	<.0001*
DJ stenting	45(100%)	45(100%)	-
Day of foleys PUC removal from surgery	2.1±0.8	2.16 ±0.9	0.739*
Day of drain removal from surgery	3.11±0.1	3.98±0.61	<.0001*
Duration of hospital stay	3.62± 1.38	4.37± 1.10	<.0001*
Serum creatinine(mg/dL)	1.1 ± 0.31	1.08 ± 0.18	0.709*
DJ stent removal at 4 weeks	45(100%)	45(100%)	-

Table 3: Comparison of post operative complications as per Clavien-Dindo Classification across both the groups(n=90)

CLAVIEN GRADE	V-Loc TM (n=45)	Vicryl(n=45)	P value
GRADE 1			
Subcutaneous Emphysema	1	1	-
Hematuria	2	2	-
GRADE 2			
Blood transfusion	-	-	-
Anastomotic leakage	-	-	-
Port site infection	-	-	-
High fever	-	-	-
Urinary tract infection	-	-	-
Pneumonia	-	-	-
Thrombophlebitis	1	1	-
GRADE 3A			
Urinoma	-	-	-
GRADE 3B			
Anastomotic leakage	-	-	-
Bleeding/hematoma	-	-	-
Colonic lesion	-	-	-
Stone formation	-	--	-

Recurrent stenosis	1	1	-
GRADE 4			
Pulmonary embolism	-	-	-
Myocardial infarction	-	-	-
TOTAL	5	5	-

Table 4: Comparison of preoperative and post-operative DTPA renogram across both the treatment groups (n=90)

DTPA Split renal function	V-Loc™(n=45)	Vicryl(n=45)	P value
Pre operative	34.64 ± 2.14	35.16 ± 2.31	0.271*
DTPA 6 weeks	44.86 ± 2.64	44.12 ± 2.38	0.166*
DTPA 3 months	44.16 ± 4.19	45.05 ± 3.97	0.304*
DTPA 6 months	44.39 ± 3.21	45.24 ± 2.96	0.195*
DTPA 12 months	45.14 ± 3.23	45.54 ± 4.17	0.612*

*Independent t test

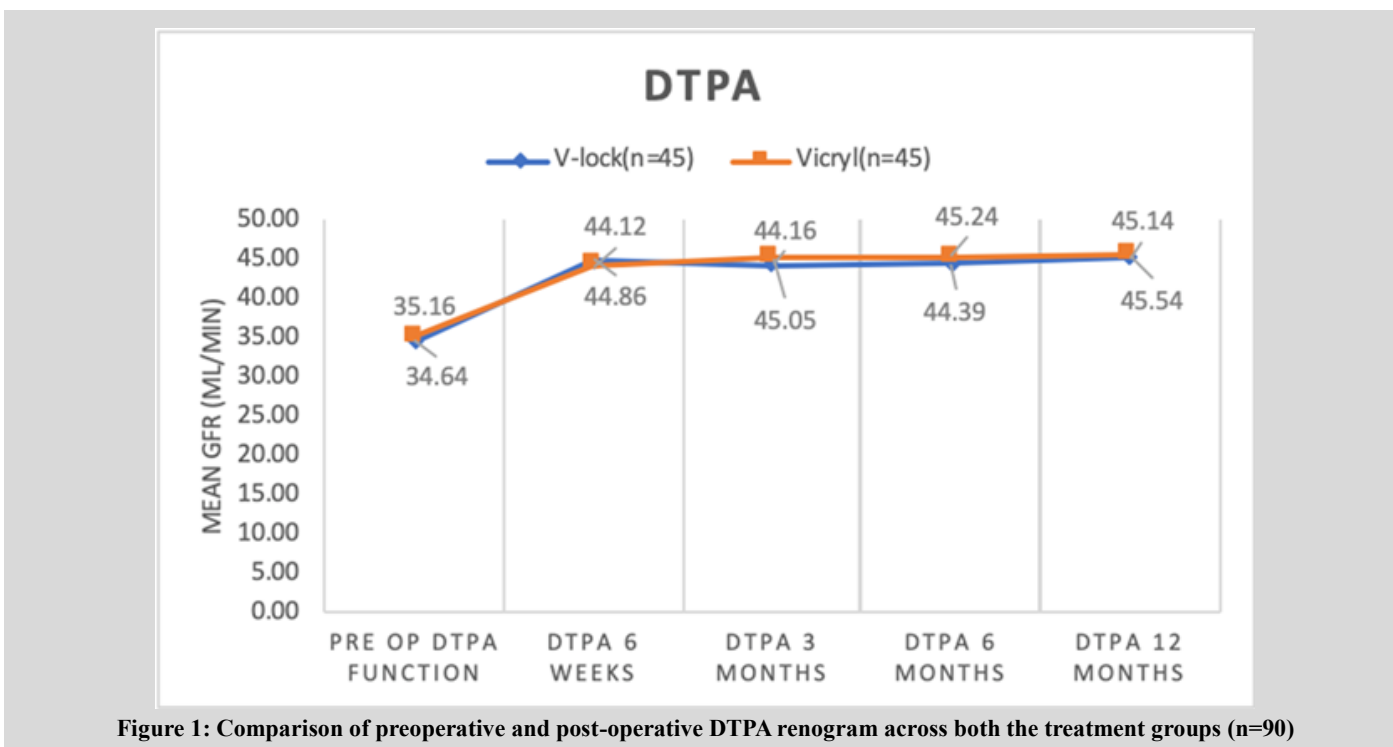


Figure 1: Comparison of preoperative and post-operative DTPA renogram across both the treatment groups (n=90)

Discussion

Use of barbed sutures for Laparoscopic intracorporeal suturing has demonstrated promising results for various urological procedures such as urethra-vesical anastomosis during robotic/laparoscopic prostatectomy and laparoscopic partial nephrectomy [4-7]. Anchoring barbs minimises loosening of the sutures preventing detachment of tissues significantly lessening the intraoperative time [8]. Such sutures resist migration, and when used in a continuous fashion without knotting, exhibit an even tissue holding performance compared with the knotted sutures [9]. Although the safety and efficacy of barbed sutures in laparoscopic pyeloplasty are confirmed in porcine models, [10] laparoscopic pyeloplasty using barbed sutures is not popular due to concerns regarding increased incidence of post-operative fibrosis and stricture formation at the anastomotic site [2]. Barbed sutures are thought to cause excessive inflammation, tearing and strangulation of tissues leading to an increased fibrotic reaction [10]. Suture line over-tightening in the hands of an inexperienced surgeon may be contributory [5]. Liatsikos *et.al*[2] found the use of barbed sutures highly unfavourable for laparoscopic pyeloplasty and attributed their failure to the surgeon learning curve required to make the transition from non-barbed to barbed sutures. However, their study had significantly small number of cohorts. Moreover, the

number of studies using barbed sutures for laparoscopic pyeloplasty are a handful to derive any conclusion [1-3].

Our study demonstrated successful outcomes using the barbed V-Loc™ suture for laparoscopic pyeloplasty in terms of hospital stay, operative time, number of sutures used and post operative complications. We did not find an increased incidence of post-operative strictures unlike Liatsikos *et al.*[2] The difference in the success rates may be owing to the use of a unidirectional barbed suture (V-Loc™) instead of the bidirectional barbed suture (Quill) as the geometry of the sutures vary considerably [11]. While V-Loc™ is cut with a dual cut angle leading to shorter and rigid barbs, Quill bidirectional barb is made with a single cut angle making it more flexible and prone to slippage [11]. In a porcine model, V-Loc™ has demonstrated strength over quill during different phases of wound healing (days 0, 3, and 7) with Quill eliciting a higher degree of fibrotic reaction [10,11]. Although the fibrosis has never been compared head to head between the Quill and V-Loc™ suture in vivo, it is interesting to note that both the studies which have demonstrated successful results following pyeloplasty conducted by Shah *et al.*[12] and Sorokin *et. al* have used V-Loc™ sutures.

Shah and colleagues [12], in their study have shown no urinary extravasation in all their patients undergoing Barbed robotic assisted laparoscopic pyeloplasty. Our study too demonstrated water

tightness with barbed sutures which was reflected in the early drain removal post procedure which was statistically significant when compared to Vicryl. This early drain removal has significantly contributed to the decrease in the hospital stay for the patient. A relative cost benefit is achieved in such patients owing to decreased OT time and decreased hospital stay despite high cost of the Barbed V-Loc™ suture when compared to the vicryl.

We, therefore, consider that using V-Loc™ barbed suture during laparoscopic pyeloplasty helps in maintaining adequate tension on the suture lines while minimizing tissue injury, and decreasing urine leakage. Use of V-Loc™ suture enables the surgeon to perform the procedure faster with atraumatic handling of the tissue which is critical for any pyeloplasty. Meticulous placement of self-anchoring knotless suture allows for eversion of the mucosal edges and a watertight anastomosis. Our results demonstrate that the laparoscopic transperitoneal laparoscopic pyeloplasty using unidirectional barbed suture(V-Loc™) is safe and feasible.

Limitations of the study

Although our study is the largest and the only study comparing the use of barbed vs non barbed sutures for laparoscopic pyeloplasty in adults, larger cohorts with long term follow up are required to draw confident conclusions. A prospective study with randomisation avoids any bias. Furthermore, a comparison of different type of barbed sutures in laparoscopic pyeloplasty needs to be studied.

Conclusion

V Loc™ barbed suture achieves successful outcomes for laparoscopic pyeloplasty in adults similar to non barbed sutures while significantly decreasing the operative times, urinary extravasation and hospital stay.

Declarations

Ethics approval and consent to participate

Obtained from the Institutional ethics Committee - Ramaiah Medical College Ethical committee, Approval number: MSRMC/EC/JA-04/188-22

Informed & written consent

Obtained to publish data

Data Availability

The datasets used and/or analysed during the current study are available from the corresponding author on reasonable request.

Competing interest

The authors declare that they have no competing interests.

Financial Support or Sponsorship

None

Authors' contributions

TJ: Concept, Design, Supervision, Resources, Writing Manuscript, Critical Review
VGH: Design, Data Processing, Analysis and/or Interpretation, Literature Search

MT: Critical Review, Data Collection, Processing, Analysis and/or Interpretation, Writing Manuscript

PS: Data Collection, Processing, Analysis

YPM: Data Collection, Processing

Acknowledgements

Nil

References

- [1] Sorokin I, O'Malley RL, McCandless BK, Kaufman RP Jr. Successful Outcomes in Robot-Assisted Laparoscopic Pyeloplasty Using a Unidirectional Barbed Suture. *J Endourol.* 2016 Jun;30(6):660-4.
- [2] Liatsikos E, Knoll T, Kyriazis I, Georgiopoulos I, Kallidonis P, Honeck P, Stolzenburg JU. Unfavorable outcomes of laparoscopic pyeloplasty using barbed sutures: a multi-center experience. *World J Urol.* 2013 Dec;31(6):1441-4. doi: 10.1007/s00345-012-1019-6.
- [3] Yilmaz O, Tanriverdi HI, Cayirli H, Ertan P, Sencan A, Genc A, Taneli C. Successful outcomes in laparoscopic pyeloplasty using knotless self-anchoring barbed suture in children. *J Pediatr Urol.* 2019 Dec;15(6):660. e1-660. e5
- [4] Kaul S, Sammon J, Bhandari A, Peabody J, Rogers CG, Menon M (2010) A novel method of urethrovesical anastomosis during robot-assisted radical prostatectomy using a unidirectional barbed wound closure device: feasibility study and early outcomes in 51 patients. *J Endourol* 24(11):1789–1793.
- [5] Williams SB, Alemozaffar M, Lei Y *et al* (2010) Randomized controlled trial of barbed polyglyconate versus polyglactin suture for robot-assisted laparoscopic prostatectomy anastomosis: technique and outcomes. *Eur Urol* 58(6):875–881
- [6] Jeon SH, Jung S, Son HS, Kimm SY, Chung BI. The unidirectional barbed suture for renorrhaphy during laparoscopic partial nephrectomy: Stanford experience. *J Laparoendosc Adv Surg Tech A.* 2013 Jun;23(6):521-5.
- [7] Erdem S, Tefik T, Mammadov A, Ural F, Oktar T, Issever H, Nane I, Sanli O. The use of self-retaining barbed suture for inner layer renorrhaphy significantly reduces warm ischemia time in laparoscopic partial nephrectomy: outcomes of a matched-pair analysis. *J Endourol.* 2013 Apr;27(4):452-8.
- [8] Sammon J, Petros F, Sukumar S *et al* (2011) Barbed suture for renorrhaphy during robot-assisted partial nephrectomy. *J Endourol* 25(3):529–533
- [9] Tewari AK, Srivastava A, Sooriakumaran P, Slevin A, Grover S Waldman O, *et al.* Use of a novel absorbable barbed plastic surgical suture enables a "self-cinching" technique of vesicourethral anastomosis during robot-assisted prostatectomy and improves anastomotic times. *J Endourol* 2010;24:1645e50.
- [10] Weld KJ, Ames CD, Hruby G *et al* (2006) Evaluation of a novel knotless self-anchoring suture material for urinary tract reconstruction. *Urology* 67(6):1133–1137
- [11] Gingras K, Zaruby J, Maul D. Comparison of V-Loc 180 wound closure device and Quill PDO knotless tissue closure device for intradermal closure in a porcine in vivo model: Evaluation of biomechanical wound strength. *J Biomed Mater Res B Appl Biomater* 2012; 100:1053–1058.

- [12] Shah HN, Nayyar R, Rajamahanty S, *et al.* Prospective evaluation of unidirectional barbed suture for various indications in surgeon-controlled robotic reconstructive urologic surgery: Wake Forest University experience. *Int Urol Nephrol* 2012; 44:775–785.



Published by AMMS Journal, this is an Open Access article distributed under the terms of the Creative Commons Attribution 4.0 International License. To view a copy of this license, visit <http://creativecommons.org/licenses/by/4.0/>.

© The Author(s) 2026